



# The Expanding Role of Vital Pulp Therapy

*Authored by Martin Trope, DMD*

**Upon successful completion of this CE activity, 2 CE credit hours may be awarded.**

---

Opinions expressed by CE authors are their own and may not reflect those of *Dentistry Today*. Mention of specific product names does not infer endorsement by *Dentistry Today*. Information contained in CE articles and courses is not a substitute for sound clinical judgment and accepted standards of care. Participants are urged to contact their state dental boards for continuing education requirements.

---

## The Expanding Role of Vital Pulp Therapy

Effective Date: 6/01/16 Expiration Date: 6/01/19

### About the Author



**Dr. Trope** was born in Johannesburg, South Africa, where he received his BDS degree in dentistry (1976) and practiced general dentistry and endodontics. He moved to Philadelphia in 1980 to specialize in endodontics at the University of Pennsylvania (UPenn). After graduating as an endodontist, he continued at UPenn as a faculty member until he became chair of endodontology at Temple University School of Dentistry in 1983. In 1993, he accepted the JB Freedland Professorship in the department of endodontics at the University of North Carolina at Chapel Hill School of Dentistry. He has also served as a director of the American

Board of Endodontics. Currently, he is a clinical professor in the department of endodontics at the School of Dental Medicine at UPenn, maintains a private practice in Philadelphia, and runs Next Level Endodontics Continuing Dental Education. He is the former editor-in-chief of 2 journals, *Dental Traumatology* and *Endodontic Topics*, and serves on the editorial board of *Oral Surgery, Oral Medicine, and Oral Pathology* and on the advisory board of *Esthetic Dentistry*. He has published more than 180 papers and written many book chapters. He can be reached via email at the address martintrope@gmail.com.

*Disclosure: Dr. Trope, as clinical director for Brasseler USA, is actively involved in the development, design, and promotion of new technological advancements in endodontics.*

### INTRODUCTION

Premixed bioceramic materials have properties that bring into question the long-held view that capping the cariously exposed pulp should not be attempted. Peri-radicular periodontitis occurs in a tooth when microbes are present in a necrotic pulp space. If the pulp is vital, peri-radicular periodontitis will not occur. Therefore, as dentists, we should try to maintain a healthy vital pulp, if it is feasible. In fact, the healthy vital pulp is the best root filling possible!

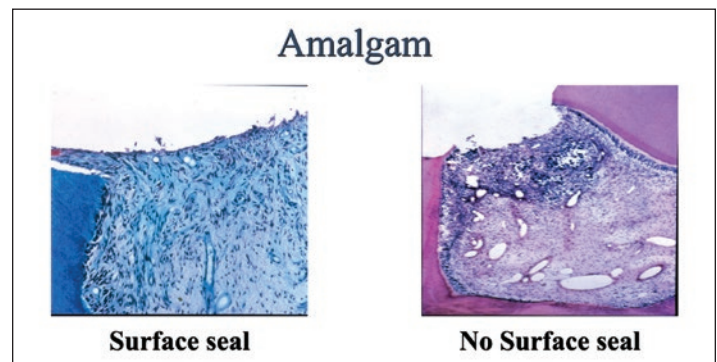
Until recently, the indications for vital pulp therapy were extremely narrow. The following 3 basic requirements were thought essential: (1) a healthy pulp before treatment, (2) a good coronal seal after treatment, and (3) the use of calcium hydroxide as the vital pulp medicament. Thus, only traumatic exposures treated in the first few hours of the incident ensured a healthy pulp, allowing for a direct pulp cap. If symptoms of pulpitis or a carious exposure even without symptoms was present, root canal treatment in mature teeth was recommended. If

the tooth was immature, a pulpotomy (not pulp cap) could be attempted in the hope that the inflammation had not spread to the root pulp.

If we examine the studies that have led to the conclusions above, some re-evaluation of the philosophy is in order. In the 1970s, a series of studies led us to the conclusion that the inflamed pulp (symptoms or carious exposure) could not be treated successfully. The studies of Tronstad and Mjör<sup>1</sup> on inflamed pulps in monkeys showed that in general, direct pulp capping was unsuccessful. Interestingly, in retrospect, the groups with calcium hydroxide capping and amalgam coronal restorations were less effective than zinc-oxide eugenol (ZOE) placed directly on the pulp. Barthel et al,<sup>2</sup> among many others generally using amalgam as the coronal seal above calcium hydroxide, confirmed that the procedure was not predictably successful in humans. This has remained the conclusion that dominates even today.

Calcium hydroxide was thought to be essential because of its predictable effect on the pulp. Since the calcium hydroxide has a pH of > 12, the superficial layer of pulp was necrosed and any microbes in this area killed.<sup>3</sup> Under the necrotic layer, a hard-tissue defensive layer was predictably produced, protecting the pulp from further damage.<sup>4</sup>

A landmark study in 1987 by Cox et al<sup>5</sup> showed that the coronal seal was the critical factor for successful pulp capping and that, in fact, almost any material (not only calcium hydroxide) was effective as a capping agent as long as the coronal seal above was adequate. They capped healthy pulps with different materials that were either used as usual (not sealed on the outside) or the same material was placed on the pulp with an external seal of ZOE. They found that all materials used as the entire seal resulted in inflammation of the pulp, whereas when a ZOE surface seal was present, all tested materials could be used as pulp-capping agents with no inflammation of the pulp (Figure 1).<sup>5</sup>



**Figure 1.** The reaction of the pulp when capped with amalgam, with a surface seal versus without a surface seal. When microbes, due to leakage, do not reach the pulp (surface seal) (left), there is no inflammation. However, when microbes do reach the pulp (no surface seal), inflammation is present (right).<sup>5</sup>

## The Expanding Role of Vital Pulp Therapy

If we take into account that most of the studies done in the 1970s concluded that vital pulp therapy was not predictable—using amalgam as the coronal seal, which the Cox et al<sup>5</sup> study showed leaked and resulted in further inflammation; and calcium hydroxide, which washes out on contact with moisture and was the capping agent—it is not difficult to understand why the procedure was not predictably successful. The example seen above with amalgam (Figure 1) was repeated with many other materials illustrating that it is the seal that is important and not the material that is placed on the pulp. However, if there were a material that, like calcium hydroxide, had a high pH when placed on the pulp, sealed the cavity like ZOE but did not wash out if challenged by saliva, there would be the possibility that capping the inflamed pulp resulted in predictable success.

### Bioceramic Technology in Endodontics

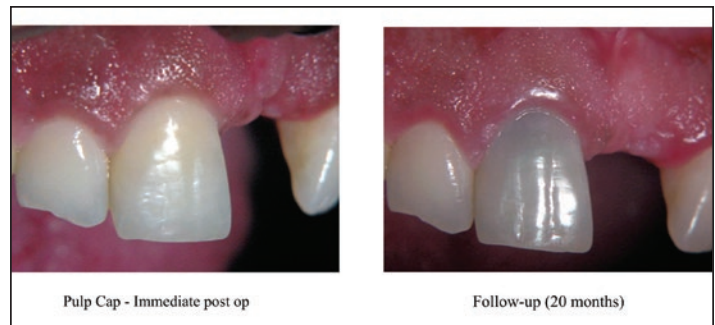
Bioceramics are ceramic materials specially designed for use in dentistry and medicine. These materials include alumina and zirconia, bioactive glass, coatings and composites, hydroxyapatite and resorbable calcium phosphates, and radiotherapy glasses.<sup>6-8</sup>

Bioceramics are used for orthopedic applications (joint or tissue replacement), and as coatings to improve the biocompatibility of metal implants. In addition, bioceramics can function as resorbable lattices, providing a framework that eventually dissolves as the body rebuilds tissue.<sup>9</sup>

Today, in dentistry and medicine, there are numerous bioceramics being used. Alumina and zirconia are bioinert ceramics used in prosthetics. Bioactive glass and glass ceramics are available under various brand names for use in dentistry. In addition, porous ceramics (such as calcium phosphate-based materials) have been employed to fill bone defects. Furthermore, some calcium silicates, like mineral trioxide aggregate (MTA [DENTSPLY Tulsa Dental Specialties]) and Bioaggregate (DiaDent), have been used for apical root filling materials and as root repair materials.

### Mineral Trioxide Aggregate

It is not well known among most clinicians, but the original MTA is a classical bioceramic material with the addition of some heavy metals. One of the most extensively researched materials in the dental field is MTA.<sup>10,11</sup> This bioceramic material has the properties found in all bioceramics, including high pH when unset, bioactive and biocompatible when set, and able to provide an excellent seal throughout time. However, it does have some disadvantages, such as the following: the initial setting time is at least 3 hours, it requires mixing (resulting



**Figure 2.** The 20-month follow-up of tooth pulp capped with MTA (DENTSPLY Tulsa Dental Specialties). Note the gray discoloration.

in considerable waste), and it is difficult to manipulate and to remove. Furthermore, both the gray and white MTA stain dentin; this is thought to occur because of the heavy metal content of the material or the inclusion of blood pigment during setting. As a result, its use in the aesthetic zone, for vital pulp therapy, is limited (Figure 2).

Bogen et al<sup>12</sup> in 2008 performed a clinical observational study with direct pulp capping on carious exposures in teeth diagnosed with reversible pulpitis. Patient ages ranged from ages 7 to 49 years with a follow-up of between one and 7 years. Overall success (no symptoms and testing vital to sensitivity testing) was 97.96% while the success after 5 years was 94%.<sup>12</sup>

Recently, new pure bioceramic materials have been introduced into the market. Biodentine (Septodont) is considered a 2nd-generation bioceramic material with similar properties to MTA and thus can be used for all the applications set out above for MTA.<sup>13</sup> Its advantages over MTA are that it sets in a shorter time (approximately 10 to 12 minutes) and has a compressive strength similar to dentin. A major disadvantage is that it must be triturated for 30 seconds in a preset quantity (capsule), making waste inevitable, since in the vast majority of cases only a small amount is required.

### Endodontic Premixed Bioceramics

The endodontic premixed bioceramics are available in North America as EndoSequence BC Sealer, EndoSequence BC RRM (Root Repair Material) (syringable), and EndoSequence BC RRM Fast-Set Putty, all from Brasseler USA.

Recently, these materials have also been made available outside North America as TotalFill BC Sealer, TotalFill BC RRM-Paste, and TotalFill BC RRM-Putty (Brasseler USA).

All 3 forms of bioceramic are similar in chemical composition (calcium silicates, zirconium oxide, tantalum oxide, calcium phosphate monobasic, and fillers) and have excellent mechanical and biological properties and good

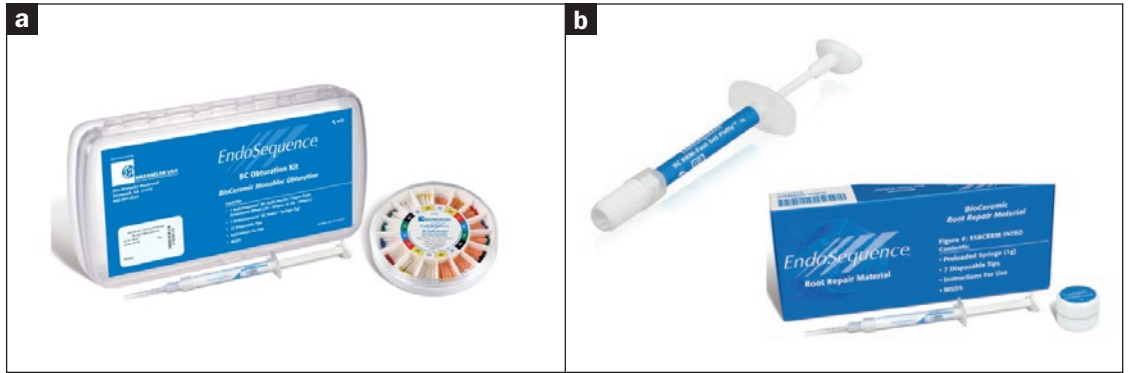
# The Expanding Role of Vital Pulp Therapy

handling properties. They are hydrophilic, insoluble, radiopaque, aluminum-free, have a high pH, and require moisture to set and harden. The working time is more than 30 minutes, and the setting time is 4 hours in normal conditions, depending on the amount of moisture available.

In addition, EndoSequence BC RRM Fast-Set Putty has recently been introduced into the market and has all the properties of the original putty but has a faster setting time (approximately 20 minutes).

BC RRM and BC RRM Fast-Set Putty are recommended for perforation repair, apical surgery, apical plug, and vital pulp therapy. Studies on the effect of this premixed pure bioceramic on pulp cells have been universally positive (Figure 3).<sup>14-16</sup>

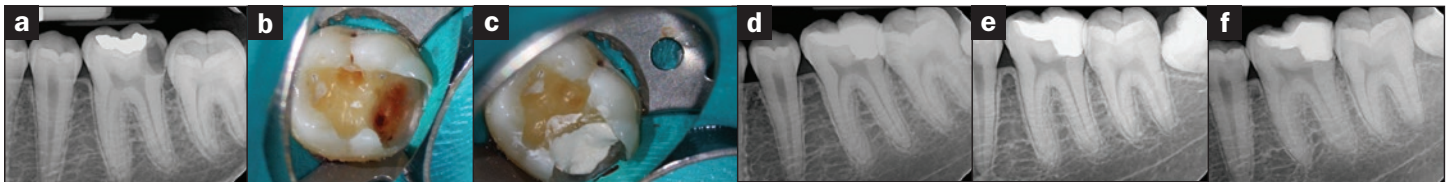
Thus, we now have a material that is ideal for vital pulp therapy, since it has a high pH when unset; is hard with an excellent seal when set, allowing for placement of a coronal restoration under ideal conditions and also ensuring the seal even if the coronal restoration breaks down throughout time; and it exhibits no discoloration, allowing it to be used in all areas of the mouth.



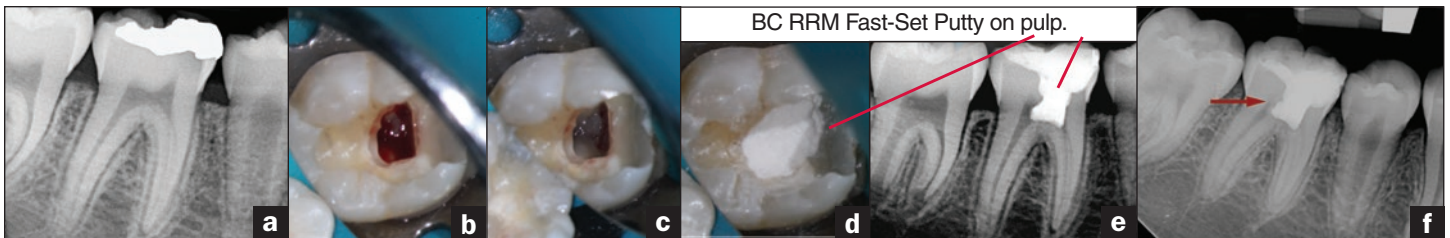
**Figure 3.** The EndoSequence BC Root Repair Materials (RRMs) (Brasseler USA). All are premixed and differ only in their flowability due to the particle size of the silicate component (EndoSequence BC RRM, RRM Fast-Set Putty, and BC Sealer (Brasseler USA)).

### CLINICAL CASE 1

Figure 4a shows the preoperative radiograph of a deep carious lesion on tooth No. 19 of a 20-year-old male patient. A diagnosis of reversible pulpitis was made based on the history and clinical exam. After anesthesia and caries removal, an exposure was seen (Figure 4b) that was covered with EndoSequence BC RRM Putty (Figure 4c). After the base had fully set, a bonded resin was placed and a postoperative radiograph taken (Figure 4d). At the 6-month follow-up visit, the tooth was asymptomatic and tested vital. The new radiograph showed no signs of pathology (Figure 4e). At 2 years postoperatively, the tooth remained asymptomatic (Figure 4f). A reparative barrier had formed below the bioceramic capping material and the canal was not calcified (this implies there was a good seal).

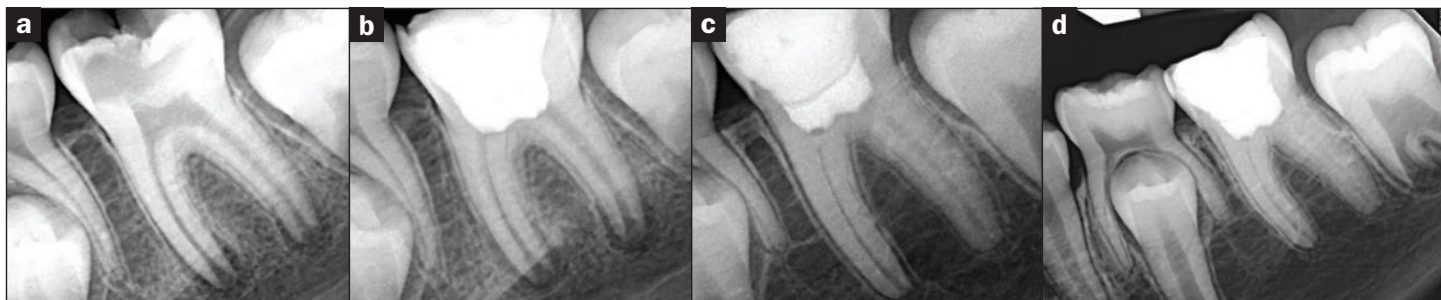


**Figure 4.** (Case 1) Pulp Cap: (a) pre-op, (b) pulp exposure, (c) EndoSequence BC RRM Fast-Set Putty (Brasseler USA) base, (d) immediate post-op, (e) 6-month follow-up, (f) 2-year follow-up. (Courtesy Dr. Mohammed A. Alharbi, Philadelphia, Pa.)



**Figure 5.** (Case 2) Cvek Partial Pulpotomy/Pulpotomy: (a) pre-op radiograph, (b) pulp exposure, (c) Cvek pulpotomy, (d) EndoSequence BC RRM Fast-Set Putty on pulp, (e) immediate follow-up, and (f) 18-month follow-up (arrow). (Courtesy Dr. Mohammed A. Alharbi, Philadelphia, Pa.)

## The Expanding Role of Vital Pulp Therapy



**Figure 6.** (Case 3) Full Pulpotomy: (a) pre-op, (b) immediate post-op, (c) one-year follow-up, and (d) 2-year follow-up. (Courtesy Dr. Guillaume Jouanny, Paris, France.)

### CLINICAL CASE 2

The preoperative radiograph shows an apparent carious exposure on tooth No. 19 of an 11-year-old male patient (Figure 5a). A diagnosis of reversible pulpitis was made based on the history and clinical exam. After anesthesia and caries removal, an exposure was visible (Figure 5b). Due to difficulty in controlling bleeding at the exposure site, a full pulpotomy on the mesial canals and a Cvek partial pulpotomy on the distal aspect of the tooth was performed to remove the superficial inflamed layer of tissue (Figure 5c). When the bleeding was controlled, the cavity was washed with sodium hypochlorite, and then the pulp was covered with EndoSequence BC RRM Fast-Set Putty (Figure 5d). After the base had set, a bonded resin was placed and a postoperative radiograph taken (Figure 5e). At the 18-month follow-up exam, the patient was found to be asymptomatic. The new radiograph showed that the apices had closed, the canals remained open, and a hard-tissue barrier had formed around the bioceramic material (Figure 5f; arrow).

### CLINICAL CASE 3

In this clinical case, the tooth tested vital but with clinical signs of irreversible pulpitis. It was decided to treat with a full pulpotomy in order to improve the chances that the remaining pulp would survive and stay healthy. The preoperative radiograph (Figure 6a) showed extensive caries in the tooth, with a widened apical periodontal ligament. A full pulpotomy was performed using the EndoSequence BC RRM Fast-Set Putty. After it was set, a coronal restoration was placed. Figure 6b shows the immediate postoperative radiograph. At the one-year follow-up, the tooth was asymptomatic, and a new radiograph (Figure 6c) showed continued root development with a healthy apical periodontium. At 2 years postoperatively, the patient remained asymptomatic, and the radiograph taken at this appointment demonstrated the continued formation of the roots (Figure 6d).

### IN SUMMARY

The new premixed bioceramic materials are able to duplicate the positive properties of calcium hydroxide on the pulp, while not washing out when exposed to fluids due to leakage. In addition, the bioceramic material itself provides a bacteria-tight base with an excellent seal, onto which a permanent restoration can be placed (under ideal conditions). Thus, previous conclusions made—that pulp capping a cariously exposed (inflamed) pulp is not possible—can now be challenged due to the superiority of the materials available today as compared to those used in the 1970s.♦

### References

1. Tronstad L, Mjör IA. Capping of the inflamed pulp. *Oral Surg Oral Med Oral Pathol.* 1972;34:477-485.
2. Barthel CR, Rosenkranz B, Leuenberg A, et al. Pulp capping of carious exposures: treatment outcome after 5 and 10 years: a retrospective study. *J Endod.* 2000;26:525-528.
3. Schröder U, Granath LE. Early reaction of intact human teeth to calcium hydroxide following experimental pulpotomy and its significance to the development of hard tissue barrier. *Odontol Revy.* 1971;22:379-395.
4. Cvek M. A clinical report on partial pulpotomy and capping with calcium hydroxide in permanent incisors with complicated crown fracture. *J Endod.* 1978;4:232-237.
5. Cox CF, Keall CL, Keall HJ, et al. Biocompatibility of surface-sealed dental materials against exposed pulps. *J Prosthet Dent.* 1987;57:1-8.
6. Best SM, Porter AE, Thian ES, et al. Bioceramics: past, present and for the future. *J Eur Ceram Soc.* 2008;28:1319-1327.
7. Dubok VA. Bioceramics: yesterday, today, tomorrow. *Powder Metallurgy and Metal Ceramics.* 2000;39(7-8):381-394.
8. Hench LL. Bioceramics: from concept to clinic. *J Am Ceram Soc.* 1991;74:1487-1510.
9. Hench LL. The future of bioactive ceramics. *J Mater Sci Mater Med.* 2015;26(2):86.
10. Torabinejad M, Parirokh M. Mineral trioxide aggregate: a comprehensive literature review—Part II: leakage and biocompatibility investigations. *J Endod.* 2010;36:190-202.
11. Parirokh M, Torabinejad M. Mineral trioxide aggregate: a comprehensive literature review—Part I: Chemical, physical, and antibacterial properties. *J Endod.* 2010;36:16-27.

## The Expanding Role of Vital Pulp Therapy

12. Bogen G, Kim JS, Bakland LK. Direct pulp capping with mineral trioxide aggregate: an observational study. *J Am Dent Assoc.* 2008;139:305-315.
13. Malkondu Ö, Karapinar Kazandağ M, Kazazoğlu E. A review on Biodentine, a contemporary dentine replacement and repair material. *Biomed Res Int.* 2014;2014:160951.
14. Zhang S, Yang X, Fan M. Bioaggregate and iRoot BP Plus optimize the proliferation and mineralization ability of human dental pulp cells. *Int Endod J.* 2013;46:923-929.
15. Torun ZO, Torun D, Demirkaya K, et al. Effects of iRoot BP and white mineral trioxide aggregate on cell viability and the expression of genes associated with mineralization. *Int Endod J.* 2015;48:986-993.
16. Shi S, Bao ZF, Liu Y, et al. Comparison of in vivo dental pulp responses to capping with iRoot BP Plus and mineral trioxide aggregate. *Int Endod J.* 2016;49:154-160.

# The Expanding Role of Vital Pulp Therapy

## POST EXAMINATION INFORMATION

To receive continuing education credit for participation in this educational activity you must complete the program post examination and receive a score of 70% or better.

### Traditional Completion Option:

You may fax or mail your answers with payment to Dentistry Today (see Traditional Completion Information on following page). All information requested must be provided in order to process the program for credit. Be sure to complete your “Payment,” “Personal Certification Information,” “Answers,” and “Evaluation” forms. Your exam will be graded within 72 hours of receipt. Upon successful completion of the post-exam (70% or higher), a letter of completion will be mailed to the address provided.

### Online Completion Option:

Use this page to review the questions and mark your answers. Return to **dentalcetoday.com** and sign in. If you have not previously purchased the program, select it from the “Online Courses” listing and complete the online purchase process. Once purchased, the program will be added to your **User History** page where a **Take Exam** link will be provided directly across from the program title. Select the **Take Exam** link, complete all the program questions and **Submit** your answers. An immediate grade report will be provided. Upon receiving a passing grade, complete the online evaluation form. Upon submitting the form, your **Letter of Completion** will be provided immediately for printing.

### General Program Information:

Online users may log in to **dentalcetoday.com** any time in the future to access previously purchased programs and view or print letters of completion and results.

## POST EXAMINATION QUESTIONS

1. In the 1970s, a series of studies led to the conclusion that the inflamed pulp (symptoms or carious exposure) could be treated successfully.
  - a. True
  - b. False
2. A landmark study in 1987 by Cox et al showed that the coronal seal was the critical factor for successful pulp capping.
  - a. True
  - b. False
3. Bioceramics can function as resorbable lattices, providing a framework that eventually dissolves as the body rebuilds tissue.
  - a. True
  - b. False
4. The use of mineral trioxide aggregate in the aesthetic zone, when using it for vital pulp therapy, is indicated, since this material will not stain dentin.
  - a. True
  - b. False
5. A major disadvantage of Biodentine (Septodont) is that it is triturated for 30 seconds in a preset quantity (capsule) making waste inevitable since in the vast majority of cases only a small amount is required.
  - a. True
  - b. False
6. EndoSequence Root Repair Material Putty and Paste (Brasseler USA) are not recommended for vital pulp therapy.
  - a. True
  - b. False
7. In case 1, a reparative barrier had formed below the bio-ceramic capping material and the canal was not calcified, implying a good seal.
  - a. True
  - b. False
8. One of the previous conclusions made—that pulp capping a cariously exposed (inflamed) pulp is not possible—can now be challenged due to the superiority of the materials available today as compared to those used in the 1970s.
  - a. True
  - b. False



# The Expanding Role of Vital Pulp Therapy

## PROGRAM COMPLETION INFORMATION

If you wish to purchase and complete this activity traditionally (mail or fax) rather than online, you must provide the information requested below. Please be sure to select your answers carefully and complete the evaluation information. To receive credit you must answer at least 6 of the 8 questions correctly.

**Complete online at: [dentalcetoday.com](http://dentalcetoday.com)**

## TRADITIONAL COMPLETION INFORMATION:

Mail or fax this completed form with payment to:

**Dentistry Today**  
**Department of Continuing Education**  
**100 Passaic Avenue**  
**Fairfield, NJ 07004**  
**Fax: 973-882-3622**

## PAYMENT & CREDIT INFORMATION:

Examination Fee: \$40.00 Credit Hours: 2  
 Note: There is a \$10 surcharge to process a check drawn on any bank other than a US bank. Should you have additional questions, please contact us at (973) 882-4700.

- I have enclosed a check or money order.
  - I am using a credit card.
- My credit card information is provided below.
- American Express    Visa    MC    Discover

Please provide the following (please print clearly):

\_\_\_\_\_  
 Exact Name on Credit Card

\_\_\_\_\_  
 Credit Card #

\_\_\_\_\_  
 Expiration Date

\_\_\_\_\_  
 Signature

This CE activity was not developed in accordance with AGD PACE or ADA CERP standards. CEUs for this activity will not be accepted by the AGD for MAGD/FAGD credit.

## PERSONAL CERTIFICATION INFORMATION:

\_\_\_\_\_  
 Last Name (PLEASE PRINT CLEARLY OR TYPE)

\_\_\_\_\_  
 First Name

\_\_\_\_\_  
 Profession / Credentials

\_\_\_\_\_  
 License Number

\_\_\_\_\_  
 Street Address

\_\_\_\_\_  
 Suite or Apartment Number

\_\_\_\_\_  
 City

\_\_\_\_\_  
 State

\_\_\_\_\_  
 Zip Code

\_\_\_\_\_  
 Daytime Telephone Number With Area Code

\_\_\_\_\_  
 Fax Number With Area Code

\_\_\_\_\_  
 E-mail Address

## ANSWER FORM: VOLUME 35 NO. 6 PAGE 82

Please check the correct box for each question below.

- |  |  |
|--|--|
| 1. <input type="checkbox"/> a. True. <input type="checkbox"/> b. False | 5. <input type="checkbox"/> a. True. <input type="checkbox"/> b. False |
| 2. <input type="checkbox"/> a. True. <input type="checkbox"/> b. False | 6. <input type="checkbox"/> a. True. <input type="checkbox"/> b. False |
| 3. <input type="checkbox"/> a. True. <input type="checkbox"/> b. False | 7. <input type="checkbox"/> a. True. <input type="checkbox"/> b. False |
| 4. <input type="checkbox"/> a. True. <input type="checkbox"/> b. False | 8. <input type="checkbox"/> a. True. <input type="checkbox"/> b. False |

## PROGRAM EVALUATION FORM

Please complete the following activity evaluation questions.

Rating Scale: Excellent = 5 and Poor = 0

Course objectives were achieved. \_\_\_\_\_

Content was useful and benefited your clinical practice. \_\_\_\_\_

Review questions were clear and relevant to the editorial. \_\_\_\_\_

Illustrations and photographs were clear and relevant. \_\_\_\_\_

Written presentation was informative and concise. \_\_\_\_\_

How much time did you spend reading the activity and completing the test? \_\_\_\_\_

What aspect of this course was most helpful and why? \_\_\_\_\_

\_\_\_\_\_  
 What topics interest you for future *Dentistry Today* CE courses?